

## Documented bites by a yellow sac spider (*Cheiracanthium punctorium*) in Italy: a case report

Papini R (1)

(1) Department of Animal Pathology, Prophylaxis and Food Hygiene, University of Pisa, Pisa, Italy.

**Abstract:** In Italy reports of human envenomations by yellow sac spiders have been sporadic. Since increasing clinical information would improve understanding of the danger of yellow sac spiders to humans, we report the case of a 7-year-old child and her father bitten by a documented *Cheiracanthium punctorium*. They developed acute persistent pain with local skin signs and numbness, and required emergency treatment. The father recovered completely within 1 to 2 hours and the child within 3 to 4 days after treatment, probably as a result of spontaneous evolution. Clinicians should be aware of the risks and immediate management of spider bites.

**Key words:** spiders, arachnidism, Italy.

### INTRODUCTION

Although most spiders are not substantially venomous, the infliction of spider bites on humans have been reported in many parts of the world (1-4). Among the most known venomous spiders are species belonging to the genera *Latrodectus* (widow spiders) and *Steatoda* (comb-footed spiders) in the family Theridiidae, *Atrax* and *Hadronyche* (funnel web spiders) from the family Hexathelidae, *Loxosceles* (brown spiders or violin spiders) of the family Sicariidae, and *Phoneutria* (Brazilian wandering spiders) from the family Ctenidae (1-3).

Some species of potentially dangerous spiders are present in some areas of Italy too, including *Latrodectus tredecimguttatus*, *Loxosceles rufescens*, and *Steatoda paykulliana* (5). In addition, there are other spiders distributed in this country whose

bites are generally considered to be medically important though less dangerous. These include *Cheiracanthium punctorium* and *Cheiracanthium mildei*, commonly known as yellow sac spiders, in the family Miturgidae (5, 6).

To the best of our knowledge, including *C. punctorium* and *C. mildei*, there have been five previous reports of yellow sac spider bites in Italy from 1990 to 2011 (7-11). Altogether, eight people were bitten, including four females, one male and three of unreported gender as well as seven adults and one child. Bites occurred mostly in Central Italy (n = 6) and far fewer in northern (n = 1) and southern (n = 1) regions, i.e. in Umbria (n = 4), Tuscany (n = 2), Apulia (n = 1), and Emilia-Romagna (n = 1). All the bites occurred between May and September, due to the fact that only adult yellow sac spiders are capable of biting (juveniles are too small) and there are

only adults in May/June, since *Cheiracanthium* spiders do not live beyond September (males) or November (females) as adults.

Since these spiders prefer to live on trees, shrubs, and low vegetation surrounding open expanses, such as fields, the highest number (n = 5) of bites in Italy occurred when people were performing outdoor activities (7, 8). *C. punctorium* specimens were found in the garden of bite victims (7, 10). Nonetheless, both *C. punctorium* and *C. mildei* were also detected inside houses in Italy while *Cheiracanthium* infestation has been reported in a locker room in the United States (9-12). This shows that *C. punctorium* and *C. mildei* may be prone to synanthropic behavior and, if there are prey available, can become indoor spiders being established inside houses and other buildings. Yellow sac spiders are active in the night, when they wander around to hunt their prey, usually small insects and possibly even other spiders. Despite this, almost the totality (n = 7) of envenomation victims in Italy were bitten during the day (7, 8, 10, 11).

Verification of spider bites requires: a bite; a spider collected during/after biting; and identification by an expert (1, 4). All these conditions rarely coincide. In addition, increasing clinical information will help elucidate the danger of yellow sac spiders to humans. Therefore, it was deemed interesting to report a documented case wherein a child and an adult were bitten by *C. punctorium* in Italy.

## CASE REPORT

At the beginning of August 2011, a 30-year-old man brought two dead spiders in a glass to our department for identification and orientation on the possible consequences of their bite. The man, who had been residing in a rural area of the province of Pisa (Tuscany, Central Italy), reported the following incident: at approximately 11 a.m. on the prior day, his 7-year-old daughter suddenly started to cry and complained of a sharp, painful sensation in the palm of her left hand as soon as she clutched the armrest of a chair in the garden.

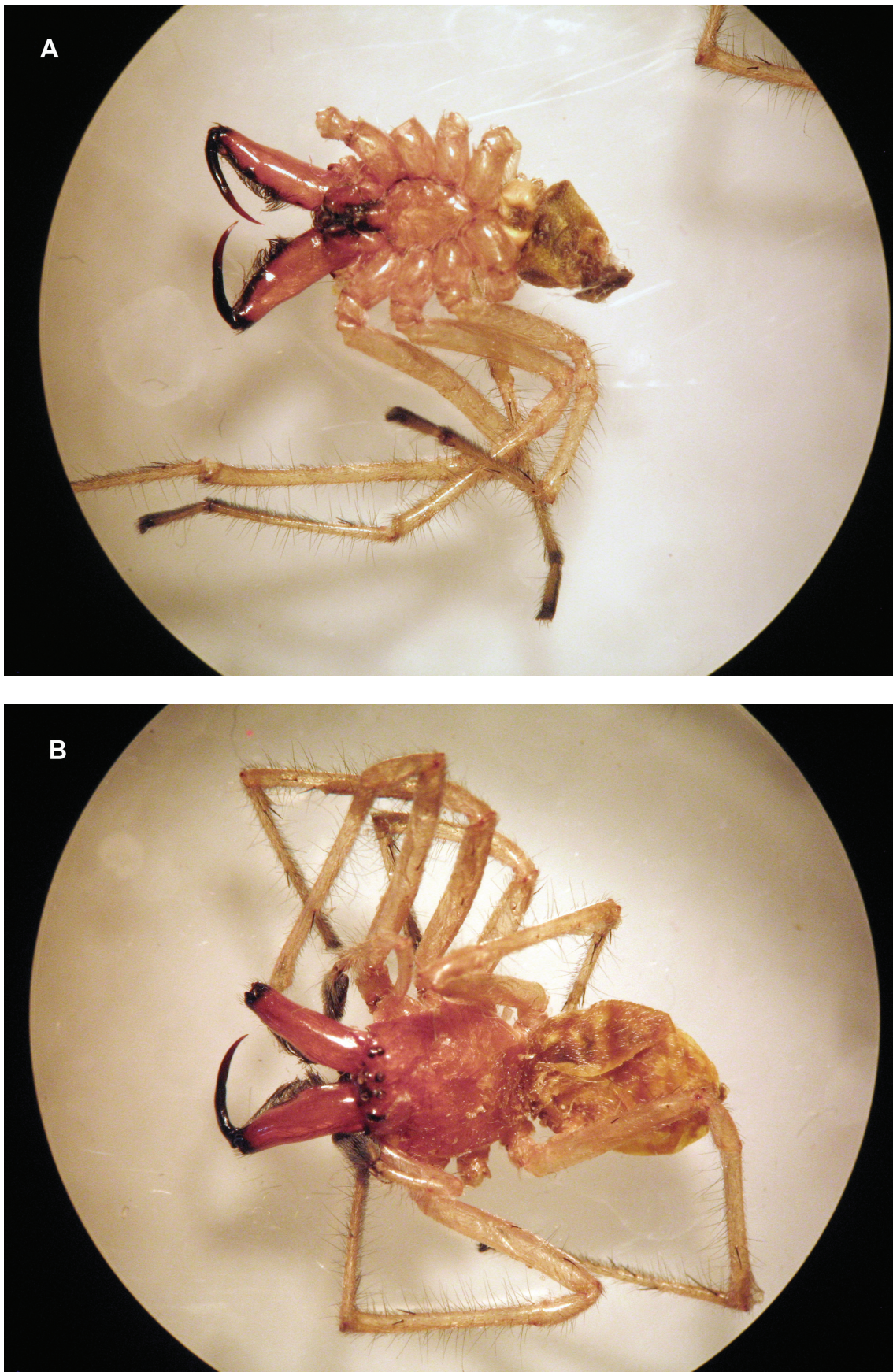
As the father did not understand the reason for such behavior, he started to touch the surface of the same armrest with his left hand, checking for the presence of causes of injuries. Shortly after, he experienced in turn a penetrating pain on the index finger, comparable to that of the sting of a

wasp. In the meantime, he saw a spider dropping to the ground. He promptly killed the spider with a slipper and then picked it up. Subsequently, during an inspection to check whether the chair was free from other spiders, he noted a white silky "cocoon" built under the garden chair armrest.

During the next 20 minutes, the appearance of redness and swelling was noted around the bite site on the left hand of both people. The father also experienced numbness in the hand. No generalized symptoms occurred. Within a few hours after the bites, the father and his daughter went to the local hospital emergency department, where they were given hydrocortisone and antihistamines followed by application of ice to the area of the bite.

Clinical signs disappeared in the father within 1-2 hours, apart from a residual and temporary paresthesia at the bite site. In contrast, clinical signs continued to be present in the child. Later that same night she was moaning in her sleep, which suggested that the bite was still painful, whereas the father could not fall asleep. Due to this episode of insomnia, the father proceeded to the garden to smoke a cigarette where he saw another spider, similar to the previous one, at the threshold of a door opening to the outside. Promptly, he killed it with a slipper and collected its remains also. The nocturnal activity of yellow sac spiders combined with a synanthropic attitude may explain why a second *C. punctorium* specimen was found at night, close to the house door of the people involved in the present bite case.

On the day of arrival, the two spiders were immediately examined by the present author for their morphological characteristics with the aid of a stereoscope (Zeiss Stemi DV4). The spiders had a very showy aspect but, as expected, they appeared to be remarkably damaged and mashed due to crushing with a slipper. One spider lacked two legs, the other spider lacked four legs and most of the opisthotoma (Figure 1). However, some morphological characters were still distinguishable. Body length (without legs or chelicerae) was about 10 mm. The chelicerae were very well-developed and yellowish in color. The rest of the body was yellowish but the cephalotorax of one specimen tended to be reddish-orange instead. The legs were long and hairy, with dark terminal-segment extremities. Based on their distinguishing characteristics, the



**Figure 1.** Specimens of *Cheiracanthium punctorium* collected after the bite and examined under a stereoscope. Though considerably damaged, it is still possible to note the well-developed chelicerae, the yellowish or reddish-orange color of different body parts, and the long hairy legs with dark terminal-segment extremities.

two specimens were identified as *C. punctorium*, a spider species previously detected in the same geographical area (10).

The man was contacted by phone the next day to tell him the outcome of the morphological examination, and one week later to get information about the course of clinical signs in the child. It was reported that the child had recovered completely within 3–4 days after the above-mentioned treatment. However, the disappearance of clinical signs in both the father and his daughter was probably the result of a spontaneous evolution attributable to the fact that corticoids and antihistamine have no effect on the venom's actions, and thus are not effective against acute envenomation. The effect on the symptoms and signs could only be achieved by the use of an antivenom, which has not been developed. The action of the venom in adults could not be as potent as observed in children, and the manifestations disappear within a shorter period of time.

## DISCUSSION

*C. punctorium* is found from Europe to Central Asia while *C. mildei*, a closely related species, is widespread throughout the Holarctic region and in Argentina (6). In addition to Italy, *C. punctorium* was implicated in bites to humans also in Austria, France, Germany, and Russia while *C. mildei* bites have been reported in various parts of the United States (4, 7–11, 13).

Other reports of bites to humans throughout the world include *Cheiracanthium inclusum* in the United States and Canada, *Cheiracanthium japonicum* in Japan, *Cheiracanthium lawrencei* in South Africa, *Cheiracanthium mordax* in the United States, *Cheiracanthium stratioticum* in New Zealand, and *Cheiracanthium* spp in Australia (4, 9, 11).

Members of the genus *Cheiracanthium* do not produce webs. Instead, they construct a typical white silky sac of about 5 cm in diameter anywhere there are places that offer protection (10). This has given the yellow sac spiders their common name. Outdoors, such sacs are usually seen in high grass, foliage or other debris, beneath the bark of trees, or under stones. Indoors, the sacs may be found in all types of corners: along baseboards, where the ceiling meets the wall, beneath and behind furniture, along soffits, beneath window sills and around

door frames.

In our report, a silky “cocoon” consistent with a typical sac was seen under a garden chair armrest. In a previous investigation in Italy, numerous sacs were identified on the surface of *Yucca aloifolia* leaves (10). Yellow sac spiders use the sac for their daytime resting and may drop to the floor to seek cover when disturbed. The sac is also used for other functions such as molting, mating, egg-laying, and hibernating. Yellow sac spiders are prone to bite defensively and the sac is aggressively defended. Therefore, one has to be careful while removing or touching sacs, mostly between August and September when females protect their eggs after mating (7, 10).

In our report, when the child and her father accidentally touched the armrest, they probably disturbed the spider which was resting inside its sac or which was a female intent on defending the eggs laid in the month of August. Some bites ( $n = 5$ ) in Italy occurred while people were trying to get rid of the spider (8, 10). Other bites in this country occurred under unexpected circumstances. A bite was inflicted on a man who was sitting on a garden chair, similarly to our report (7). In the only case that took place at night, a *C. punctorium* specimen entered a bed and bit a woman while she was asleep (9). Another woman was bitten while she was getting dressed in pants that contained a *C. mildei* specimen (11). *C. mildei* may bite people one or more times (11).

To the best of our knowledge, this is the first report of a single *C. punctorium* specimen which bit two people within a very short interval. The chelicerae of yellow sac spiders are powerful and large enough to penetrate human skin quite easily in every body part. A majority ( $n = 4$ ) of bites in Italy occurred on the hand region, including fingers ( $n = 3$ ) and palm ( $n = 1$ ), followed by the thigh ( $n = 2$ ) and eyelid ( $n = 1$ ) regions, while some ( $n = 3$ ) bite sites were not reported.

Investigation of the toxic components contained in the venom of yellow sac spiders has revealed the presence of two major toxic fractions: the high molecular weight fraction contains a phospholipase A<sub>2</sub> whereas the main component of the other fraction is a novel and unique two-domain polypeptide (14, 15). The most typical symptom of a yellow sac spider bite is an instant, intense, stinging, painful sensation from the outset, not unlike that of the sting of a wasp, bee or hornet (7–11). This may be followed by

localized swelling, burning, redness (erythema), and/or itching near the bite site (7-11).

In some cases, it has been reported that manifestations extended from the bite site to other parts of the body: i.e. from the tip of a finger of the left hand to the whole left forearm, and from the right upper eyelid to the face, neck, and upper third of the chest (8, 9). Moreover, evolution into a necrotic lesion at the bite site of about 15 mm in diameter has been documented (8, 9, 11).

Furthermore, similar findings have recently been reported in the United States (12). However, the necrotic nature of yellow sac spider bites has been disputed. A prospective study found that none of twenty documented bites by *Cheiracanthium* caused dermonecrosis in Australia or the United States, and the authors found only one documented *Cheiracanthium* bite, out of 39 reported in the international literature, which was responsible for causing a small necrotic lesion nearly 50 years ago (4, 16). None of the other spider bites was diagnosed according to current standards of spider identification (4).

According to current knowledge, only *Loxosceles* venom causes necrosis (due to sphingomyelinase D injection). Clinical findings of this and other Italian reports support the conclusions of these authors (4, 7, 9, 10). Nonetheless, the venom of yellow sac spiders can sometimes produce no long-term neurological effects such as numbness or paresthesia of the affected limbs (7, 8). Transient spasm of both hands due to *C. punctorium* bite and lethargy alternating with hyperexcitability in case of *C. mildei* bite have also been reported (8, 9). When systemic effects were reported, they included shivers, sweat, vomiting, mild to high fever, tachycardia, neutrophilia, increase of total bilirubinemia as well as respiratory difficulty and even circulatory breakdown (7- 9). However, no fatal incidents due to yellow sac spiders have ever been recorded.

Pain and other local manifestations usually disappeared between 1-2 hours and 3-4 days but cutaneous and neurological signs disappeared after ten days in one case (7-10). In another case, swelling was still present after about two months (10). When a *C. mildei* bite occurred, skin lesions took a month and a half to heal, and scars were still visible after about five and a half months (11).

## CONCLUSIONS

Altogether, the present clinical findings and those of previous reports show that yellow sac spider bites cause immediate pain frequently associated with local and transient cutaneous and neurotoxic effects, but sometimes may also cause systemic effects. Some factors may account for this variability in severity of clinical signs. For instance, the severity of clinical signs may depend on the bite site or on underlying health problems. Some populations of yellow sac spiders might be more dangerous to humans.

It is likely that the prompt initiation of adequate treatment decreases the severity of the symptoms and improves the outcome. It is also possible that clinical signs vary from individual to individual depending on the reaction to the venom, given that more susceptible individuals can have stronger reactions. Probably, a substantial number of cases or studies are still needed to fully understand the effects of yellow sac spider bites on humans. Until a definitive conclusion is reached, because of the possibility of appearance of systemic effects, it is advisable that any person receiving a yellow sac spider bite consult a physician for treatment.

## ACKNOWLEDGMENTS

The author wishes to thank the anonymous reviewers for carefully reviewing the manuscript and improving its quality with their comments and suggestions.

## COPYRIGHT

© CEVAP 2012

## SUBMISSION STATUS

**Received:** March 16, 2012.

**Accepted:** May 28, 2012.

**Abstract published online:** June 4, 2012.

**Full paper published online:** August 31, 2012.

## CONFLICTS OF INTEREST

The author declares no conflicts of interest.

## CONSENT

Written informed consent was obtained from the patient for publication of this case report and the accompanying images.

## CORRESPONDENCE TO

Roberto Papini, Dipartimento di Patologia Animale, Profilassi e Igiene degli Alimenti, Università di Pisa, Facoltà di Medicina Veterinaria, Viale delle Piagge 2, 56124 Pisa, Italia. Phone: +39 050 2216948. Fax: +39 050 2216941. Mobile: +39 347 8712812. Email: rpapini@vet.unipi.it.

## REFERENCES

1. Isbister GK, White J. Clinical consequences of spider bites: recent advances in our understanding. *Toxicon*. 2004;43(5):477-92.
2. Nimorakiotakis, B, Winkel KD. Spider bite: the redback spider and its relatives. *Aust Fam Physician*. 2004;33(3):153-7.
3. Swanson DL, Vetter RS. Loxoscelism. *Clin Dermatol*. 2006;24(3):213-21.
4. Vetter RS, Isbister GK, Bush SP, Boutin LJ. Verified bites by yellow sac spiders (genus *Cheiracanthium*) in the United States and Australia: where is the necrosis? *Am J Trop Med Hyg*. 2006;74(6):1043-8.
5. Trotta A. Introduzione ai ragni italiani (Arachnida Araneae). *Mem Soc Entomol It*. 2005;83:3-178.
6. Platnick NI. The world spider catalog, version 12.5. American Museum of Natural History. Available from: <http://research.amnh.org/iz/spiders/catalog>.
7. Trentini M, Canestri Trotti G. Un caso di aracnidismo da *Cheiracanthium punctorium* (Villers 1798) (Araneae, Clubionidae). *Biol Oggi*. 1990;4(2-3):55-7.
8. Principato M, Polidori GA, Ubertini S. *Cheiracanthium punctorium* Villers (Araneae: Clubionidae): first note in Umbria on four cases of human envenomation. *Parassitologia*. 1994;36(Suppl 1):120.
9. Stingeni L, Giorgi M, Principato M. Aracnidismo da *Cheiracanthium punctorium* (Aranea: Clubionidae): descrizione di un caso. *Ann Ital Dermatol Clin Speriment*. 1998;52:79-81.
10. Bisconti M, Silvi E, Carnieri E, de Loewenstern AB. Segnalazione di *Cheiracanthium punctorium* Villers, 1769 (Arachnida, Araneae, Miturgidae) tra Livorno e Pisa. *Quad Mus St Nat Livorno*. 2006;19:57-64.
11. Pepe R, Trentini M. Un caso di aracnidismo necrotico da *Cheiracanthium mildei* L. Koch 1864 (Araneae, Clubionidae) nel Salento. *Thalassia Salent*. 2002;26:45-51.
12. Divito SJ, Haught JM, English JC, Ferris LK. An extensive case of dermonecrotic arachnidism. *J Clin Aesthet Dermatol*. 2009;2(9):40-3.
13. Fasan M, Rennhofer A, Moser B, Röggl G. Spider myths and a case of a bite by a yellow sac spider. *J Am Board Fam Med*. 2008;21(1):78.
14. Foradori MJ, Smith SC, Smith E, Wells RE. Survey for potentially necrotizing spider venoms, with special emphasis on *Cheiracanthium mildei*. *Comp Biochem Physiol C Toxicol Pharmacol*. 2005;141(1):32-9.
15. Vassilevski AA, Fedorova IM, Maleeva EE, Korolkova YV, Efimova SS, Samsonova OV, et al. Novel class of spider toxin: active principle from the yellow sac spider *Cheiracanthium punctorium* venom is a unique two-domain polypeptide. *J Biol Chem*. 2010;285(42):32293-302.
16. Maretic Z. *Chiracanthium punctorium* Villers – eine europäische Giftspinne. *Med Klin*. 1962;37:1576-7.